

# How to Succeed With Ultrasound Biomicroscopy

A look at the clinical and billing techniques needed to incorporate this technology in your practice.

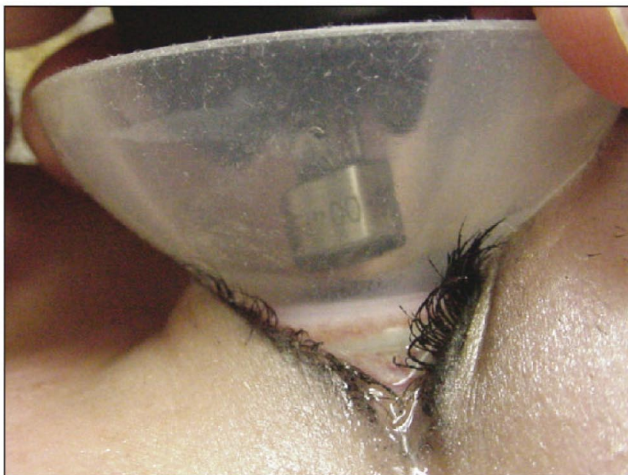---

BY THOMAS C. PRAGER, PhD, MPH

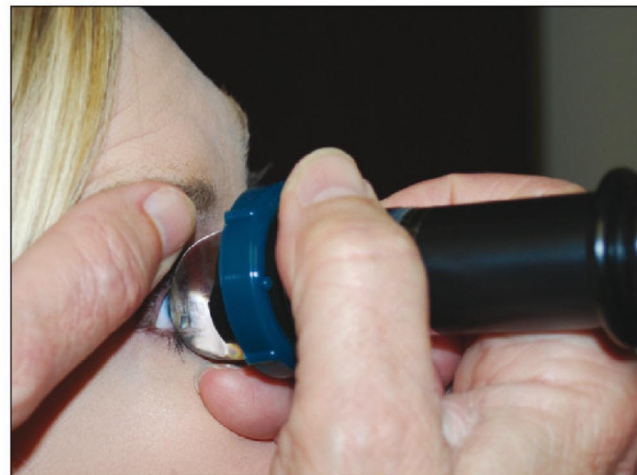**U**ltrasound biomicroscopy, or UBM, has found increasing clinical application and acceptance because of its cost effectiveness. Additionally, UBM has a distinct advantage over anterior segment optical coherence tomography due to its use of high-frequency sound waves rather than coherent light to obtain images posterior to the iris, including the angle, ciliary body, crystalline lens or an intraocular lens.

UBM is commonly used in cataract and refractive surgery to evaluate phacomorphic lens changes, dislocated

IOLs, misplaced haptics, sulcus-to-sulcus measurements for implantable contact lenses, ciliary body cysts before lens implantation, fibrin/retained lens fragments and anterior effusions. Other clinical applications include delineating corneal and anterior retinal pathology. Particularly in glaucoma patients, UBM allows visualization and detection of the angle, aqueous misdirection, position of the ciliary body in patients with plateau iris, iris/ciliary body cysts as well as the identification of ciliary body tumors, clefts and anterior retinoschisis.



**Figure 1.** Shell and gel prevents near-field artifacts but can cause a corneal abrasion, corneal “tenting” and other problems.



**Figure 2.** The ClearScan probe cover is safer, more comfortable and less traumatic than shell and gel.

To help get UBM up and running in your practice, this feature reviews different UBM techniques, in addition to what you should know before purchasing a device and how to bill for related procedures.

### ClearScan vs. Open-Shell Techniques

Greater use of UBM is due, in part, to the advent of the ClearScan cover, manufactured by ESI, Inc. of Plymouth, Minn. This FDA-approved sterile bag has been shown to be safer, more comfortable and less traumatic than the open-shell and gel technique for UBM.

When examining the angle or other ocular structures by UBM, an open shell filled with methylcellulose gel and/or saline (**Figure 1**) or a ClearScan cover (**Figure 2**) is required to overcome near-field artifact, an acoustic “dead zone” due to interfering sound waves. With the open shell, corneal abrasions may result if either the probe, often with an exposed moving nub, or the bottom edge of the shell makes contact with the corneal epithelium. The problem is exacerbated if the structure of interest is posterior to the limbus, requiring the patient to move the eye off-center. Also, the shell and gel technique may cause “tenting” or folding of the cornea, mechanically narrowing the angle due to excessive pressure on the eye to keep shell fluid from escaping.

A study<sup>1</sup> compared patient acceptance and measurement accuracy between the ClearScan and the shell and gel techniques. It found that 100% of the cohort of 20 subjects preferred the ClearScan bag/balloon methodology over the open shell technique. The average comfort rating for the ClearScan on a scale of 0 to 5, with 5 being the most aversive, was 0.40 (SD 0.52) vs. 2.95 (SD 0.90) for the open shell method, which was significant by paired t-test analysis ( $t=11.27$ ,  $p<0.0001$ ).

The less invasive attributes of the ClearScan methodology were more acceptable to patients and perceived as relatively painless both during and following the procedure, after the topical anesthesia had subsided. In contrast, the open shell technique has a rigid open rim at the bottom of the cylinder that increases the likelihood of corneal abrasion due to direct contact with the corneal epithelium. While there is a short learning curve to master the bag/balloon methodology, optimal internal bag pressure can differ from patient to patient. For accurate measurements, it is important that the ClearScan’s bag pressure is lower than the IOP of the patient to prevent denting the cornea and narrowing the angles. Internal bag pressure can be adjusted three ways:

- Fill the bag to the bottom of the collar and insert the probe so the end is about one inch from the bag’s bottom. Grab the green securing collar with your thumb and forefinger and pinch the collar — fluid and air will be released.
- Adjust the fill level.
- Push the probe inward to increase pressure or withdrawal slightly to decrease pressure.

The ClearScan allows the patient to be examined sitting up, in the same orientation as when the eye is examined by the ophthalmologist. Additionally, ClearScan technology has the potential to extend the clinical reach of UBM because ocular structures 10mm peripheral to the limbus can be readily visualized without fear of causing a corneal abrasion. Recent trabeculectomy blebs and blebs over the plate of glaucoma drainage devices can be safely imaged. In addition, basal cell carcinomas on the eyelids, cheek or side of the nose can be examined and measured prior to excision. Instructional videos can be found on YouTube by searching “ClearScan cover,” or try these three links:

- <http://www.youtube.com/watch?v=m8AOVz8tpsI>
- <http://www.youtube.com/watch?v=Hr62Ry0VmcM>
- <http://www.eyesurgin.com/libvidpict2.html>

Since ultrasound probes cannot be readily sterilized, there is potential for microbial transfer. A recent study<sup>2</sup> (in press) recommends that the ClearScan be discarded after a single use to prevent transfer of microorganisms from patient to patient. After a 10-minute UBM examination, growth was observed from cultures swabbed from the bag’s exterior surface in 28 (82%) of bacterial plates at 72 hours and isolates were classified as skin and/or ocular surface commensals. While 57% of cultures had minimal growth, moderate growth was seen in 27% of cultures.

### Think Before You Buy

There are many excellent UBM machines on the market. Base your decision primarily on which instrument provides the best image and has logical, easy-to-use software. Also consider probe frequency — the higher the frequency, the greater the resolution, but depth of penetration is reduced (**Figure 3**).

In some cases, a 50 MHz probe may not allow visualization of the posterior capsule, a drawback when examining the phacomorphic glaucoma patient. A 25 MHz probe may be an adequate general purpose tool, but if your priority is to have the greatest resolution, consider a 50 MHz probe and use ultrasound immersion biometry or coherent light (eg, Lenstar/IOLMaster) to obtain lens thickness. Having both 25 and 50 MHz probes might be the optimal choice for some clinics.

### Clinical Examples

A patient who presents with persistent eye pain after cataract surgery may have an IOL haptic making direct contact with the ciliary body. UBM can readily visualize structures posterior to the iris in contrast to coherent light technology. To save time, prior to the UBM examination know the location of the haptics from reading the chart notes or visual slit lamp inspection.

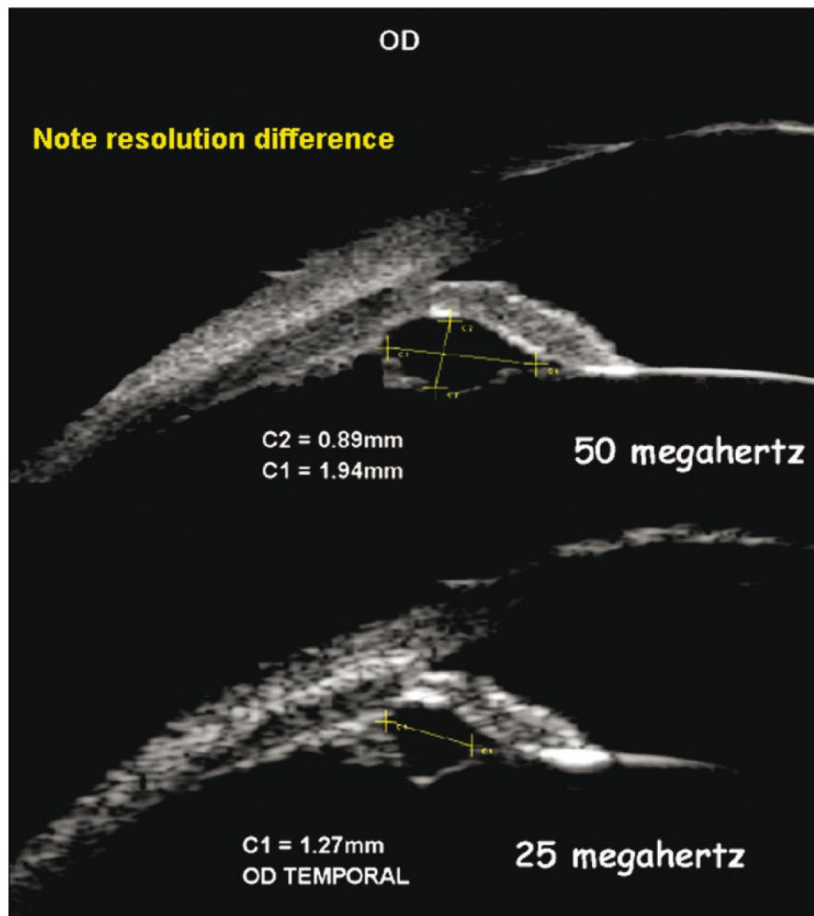


Figure 3. Resolution difference noted between 25 MHz and 50 MHz imaging.

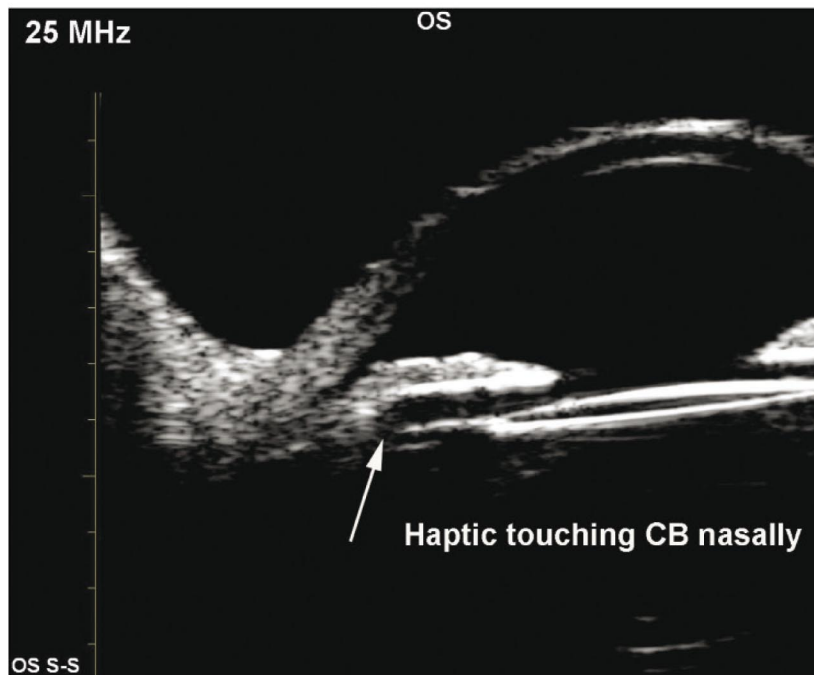


Figure 4. IOL haptic touching the ciliary body.

The first ultrasound “shot” is sulcus-to-sulcus to see if the lens is centered and to be assured the optic is not chafing against the posterior iris. Next, direct the probe to the haptic and ciliary body. For most probes, the white line on the side should face or abut the cornea at the clock hour location of interest. The anterior chamber will always appear on the right side of the screen and the sclera on the left. For instance, if one haptic is located temporally, repeat at 90 degrees away at the other haptic location nasally (Figures 4-5).

To determine if the angle is open or closed in a glaucoma patient, it is imperative to identify the location of the scleral spur, the gateway to the anterior chamber. Even with a 50 MHz probe, this subtle structure may not be visible and its location must be estimated. Differences in tissue structure or composition are discernable via ultrasound (Figure 6). One can readily appreciate the tissue difference between scleral and uveal tissues as depicted in Figure 6. The scleral spur is located on this tissue separation line approximately 1 mm proximal from the limbus. Turn down the gain to discern the beginning of the sclera as opposed to the cornea and use the caliper tool to measure back 1 mm. The intersection of the uveal/scleral line back 1 mm from the limbus is the approximate location of the spur. Perform this examination with the room lights off to maximally crowd the angle. Also note if the sulcus is visible or whether the ciliary body is rotated forward as found with plateau iris (Figure 7).

### Billing for UBM

There seems to be confusion about billing for UBM since, at this time, it is the only ultrasound procedure that reimburses for each eye. Depending on locale, one can expect to receive nominally \$85 per eye. Code 76513 is an open code that should be used for UBM; in our experience, there have been few problems receiving insurance reimbursement.

An occasional problem may occur when performing both a B-scan (76512) to examine the posterior aspects of the eye and UBM (76513). Both exams in the same patient on the same day may result in a denial, as these two ultrasound procedures are bundled. Generally, these tests are both paid on the

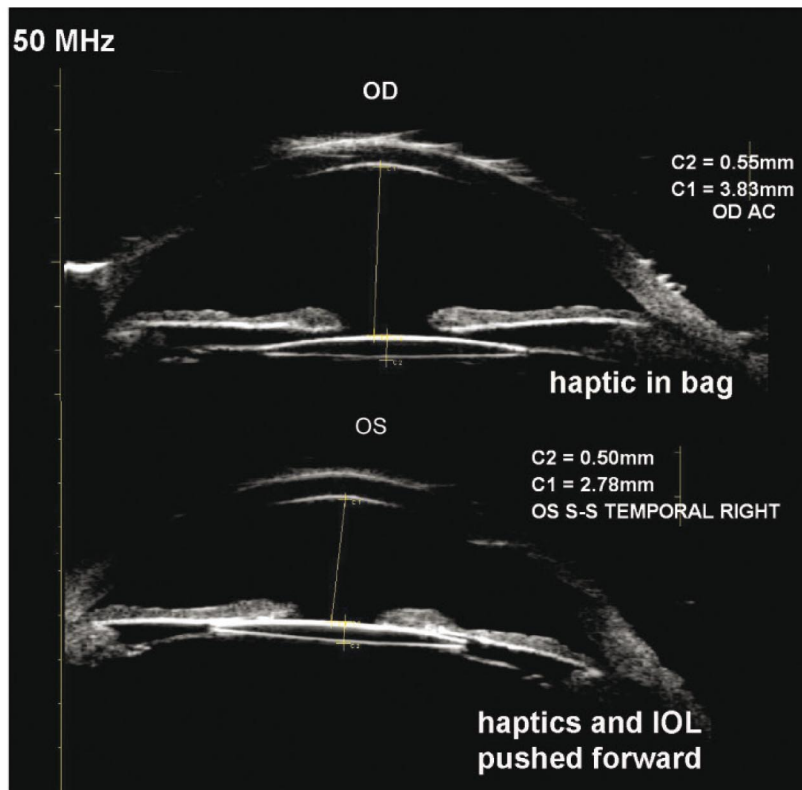


Figure 5. IOL in place (top image) vs IOL pushing forward (bottom image).

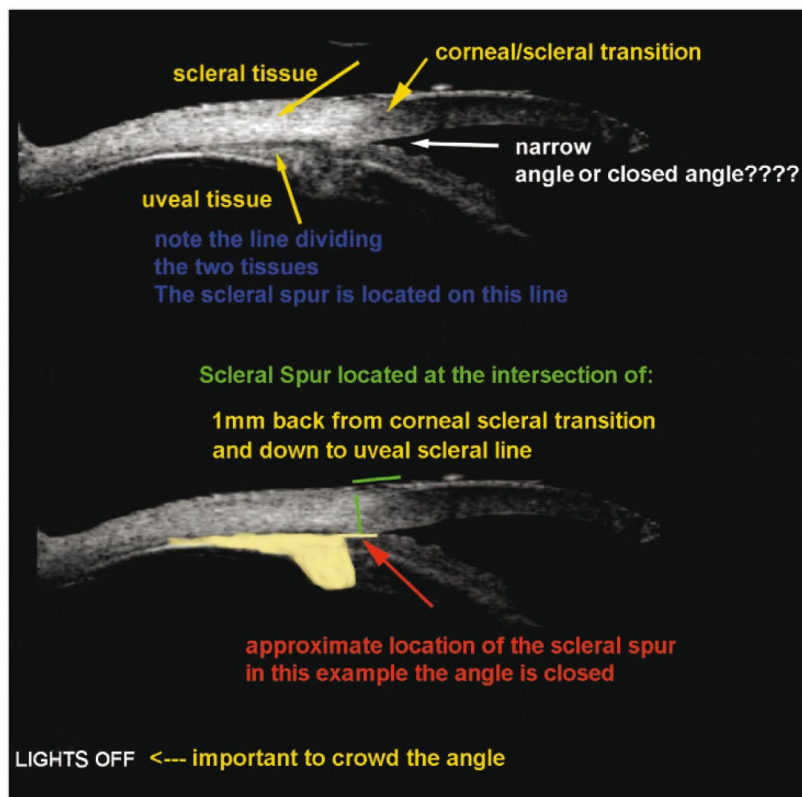


Figure 6. How to identify scleral spur location using UBM.

second appeal, but will require an accompanying standard letter explaining the separate nature of the two ultrasound exams. Alternatively, try using modifier 59 to indicate that the procedure should be unbundled and paid separately.

Here are answers to a few commonly asked questions regarding UBM billing.

**Q. How will the new ICD-10 codes affect CPT 76513?**

**A.** Effective October 1, 2013, use of ICD-10 is mandatory and diagnoses will require more detail.

**Q. Can an office visit and a UBM test be billed at the same visit?**

**A.** Both the office visit and UBM may be billed even if performed on the same day as long as there is medical necessity for each service.

**Q. How does the global period of a surgical procedure effect payment?**

**A.** The payment for any diagnostic test during the global period is once again dependent on the insurer's determination of whether or not there is medical necessity for the test. For Medicare, this often is regulated in the Local Coverage Determination. For example, after cataract surgery and within the global period, a patient reports eye pain. To determine the cause of the problem (eg, this may be due to the haptic touching the ciliary body or iritis), a UBM is performed. The diagnostic test will be paid. However, the office visit will be denied during the global period since 20 percent of the global fee for the surgery is dedicated to postoperative management that includes the office visit.

**Q. Does there have to be a clinical diagnosis or can a UBM exam be performed as part of a screening exam routinely?**

**A.** If the diagnosis is not covered for payment for CPT code 76513 by the insurer, then it will not be paid. Commercial payers often reject the claims as being experimental. Screening examinations are not covered by Medicare with the exception of glaucoma screening. However, note that a patient who presents with open-angle glaucoma generally should not receive a UBM as the information gleaned will not provide additional clinically useful information. It is not recommended to perform a UBM in open-angle glaucoma patients, who comprise 70% to 80% of the glaucoma population.

**Q. If bilateral procedures are performed, can you bill for two procedures on the same day? Can other diagnostic tests performed on the same day be paid?**

**A.** If there is medical necessity, not just that you want a comparison, Medicare pays at 100 percent of the allowable for each eye using code 76513. Other diagnostic tests performed on the same visit may be paid if deemed medically necessary and are not bundled.

**Q. Are there office visit codes that exclude using CPT code 76513 at the same visit?**

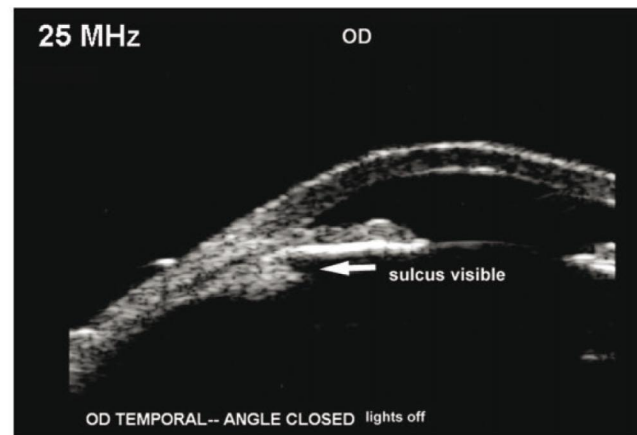


Figure 7. Visible sulcus in an angle closure patient.

**A.** Yes, there are. It is imperative to check the “bundles” on the NCCI (National Correct Coding Initiative). For example, gonioscopy is not bundled but OCT is.

**Q. Does the doctor have to be present at the exam to bill 76513, or can a technician perform it? Is the test reimbursed at the same rate if a tech performs the exam?**

**A.** While this code does not require that the doctor actually perform the test, the physician must order the test and provide an interpretation and report to receive both the technical and professional fees. For Medicare, the test is designated as being under “Direct Supervision,” which states the physician must be present in the office suite and immediately available to furnish assistance and direction throughout the performance of the procedure. It does not mean that the physician must be present in the room when the procedure is performed.

**Q. Is there a supply code (or “V” code) to cover the costs of the disposables?**

**A.** Supplies and disposables are included into the 76513 CPT code as part of the practice expense and are not reimbursed separately. Neither Medicare nor private carriers pay any portion of the supply costs.

## Conclusion

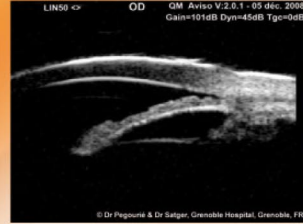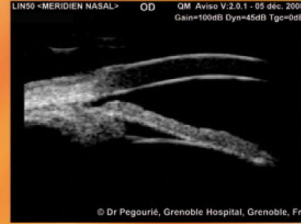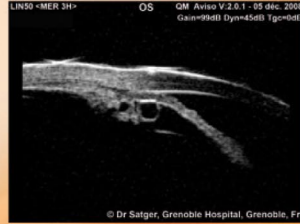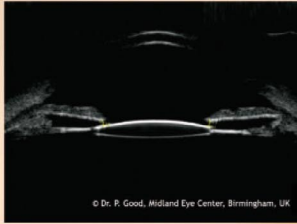
The UBM with bag/balloon technology is a hammer looking for a nail because of the many clinical questions that can be answered efficaciously, quickly, safely and comfortably with relatively inexpensive equipment. **OM**

## References

1. Bell NP, Feldman RM, Zou Y, Prager TC: A New Technology for Examining the Anterior Segment by Ultrasonic Biomicroscopy. *J Cataract Refract Surg.* 2008;34(1):121-5.
2. Bell NP, Anand A, Wanger A, Prager TC: Microbial Contamination of Ultrasound Biomicroscopy Probes: An Evaluation of Cross-infection Risk. *JCRS*, In press.

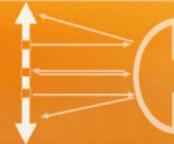Thomas Prager, PhD, MPH, is a clinical associate professor of ophthalmology at the University of Texas Medical Branch-Galveston. His expertise is in non-invasive clinical testing, including electrophysiology and ultrasonography. He can be reached at tprager@hotmail.com.

# Specially Designed for the Glaucoma Specialists



LIN 50 already used in the following reference centers:

- Cleveland Clinic
- Mayo Clinic
- Wills Eye
- Doheny Eye Institute
- Ohio State Univ
- Univ of Minnesota
- Methodist Hospital - Houston
- Ochsner Clinic - New Orleans
- McGill Univ - Montreal
- Ike Ahmed, MD
- Tom Prager, PhD
- Etc .....



## Lin 50 UBM

Linear UBM probe

**Aviso exclusive**

Linear Technology:  
High Resolution Imaging and Accuracy  
from Cornea to Ciliary Bodies

Compatible with ClearScan® Probe Cover

**Quantel**  
medical

For more information, visit [www.quantel-medical.com](http://www.quantel-medical.com)